

Mycobacterium Chelonae Line Sepsis In A 4 Year Old Male With Acute Myeloid Leukaemia (AML)

Gilbert Mogoko*, Syed Imam, Khalid Rahman and Emmanuel Babafemi

Liverpool John Moore University, United Kingdom.
Mid and South Essex NHS Foundation, United Kingdom.

Corresponding Author:

Gilbert Mogoko,
Liverpool John Moore University, United Kingdom
Email: g_mogoko@yahoo.co.uk; g.m.mogoko@2021.ljmu.ac.uk

Received Date: 01 Dec 2023

Accepted Date: 15 Dec 2023

Published Date: 22 Dec 2023

Citation:

Gilbert Mogoko. Mycobacterium Chelonae Line Sepsis In A 4 Year Old Male With Acute Myeloid Leukaemia (AML). International Journal of Clinical and Medical Case Reports 2023.

1. Abstract

1.1 Background:

Mycobacterium chelonae (MC) was isolated from an immunosuppressed four-year-old with Acute Myeloid Leukaemia. This was initially dismissed as gram positive bacilli diptheroid based on gram staining. Several more blood culture bottles flagged up positive in quick succession. A review of the gram stain with additional ZN staining revealed acid-fast bacilli and finally identified as Mycobacterium chelonae.

1.2 Case presentation:

A 4-year-old (now 5) male with acute myeloid leukaemia presented to Emergency department at Southend hospital with febrile non-neutropenia/low grade fever, loss of appetite, weight loss and general weakness. Suspected Sore and infected gastrostomy site, with percutaneous endoscopic gastrostomy (PEG). Blood cultures were collected and patient put-on broad-spectrum antibiotics and antifungal. 5 sets yielded Mycobacterium chelonae. The patient was kept on broad spectrum antibiotics with additional meropenem, removal of PEG and follow up blood cultures were negative.

1.3 Conclusion:

Nontuberculous mycobacteria, particularly fast growers, should be considered or excluded by ZN staining in positive cultures after 2-4 days from immunosuppressed patients with gram positive rods (GPRs) on gram staining, this is even more necessary if patients have lines insitu. Several multiple sets of blood culture will also be helpful to rule

out contamination. Laboratories should attempt to identify NTM by Matrix Assisted Laser Desorption-Time of Flight (MALDI-TOF) by full extraction if available. If the isolate is considered clinically significant, a full antibiotic susceptibility should be sought to guide therapy.

2. Key words:

Fast growers, immunosuppressed, acute myeloid, leukemia, line, myeloblasts.

3. Background

Mycobacterium chelonae is a species of rapidly growing mycobacteria that can cause infections in humans. It is commonly found in soil, water, and dust and can cause a range of infections, including skin and soft tissue infections, pulmonary infections, and disseminated infections. In this case study, we will focus on a patient who presented with a positive blood culture for M. chelonae. Mycobacterium chelonae was first isolated from a sea turtle by Friedman in 1903 (Brown-Elliott and Philley 2017). It was first recognised as a species in 1923 (Männikkö 2011) and described in more detail in 1972 (Stanford, Pattyn et al. 1972). It is classified as rapid grower nontuberculous mycobacterium (NTM), Runyon class IV. This group of rapid growers include Mycobacterium abscessus and Mycobacterium fortuitum. Till 1992 M chelonae and M abscessus were considered identical and now can be differentiated by intergenic sequence (ITS), hsp65 or gene sequence (Kusunoki and Ezaki 1992). Though not ideal, antibiotic susceptibility profiles can also be useful in differentiating between M chelonae and M abscessus. M chelonae exhibits high cefoxitin MIC, MIC >64 mg/L and Low tobramycin MIC, MIC <4mg/L, whereas M abscessus has a low cefoxitin MIC, MIC <64 mg/L and resistant to tobramycin with an MIC >8mg/L (Akram, Rathish et al. 2017) another important biochemical feature to help in differentiating the two is utilization of citrate. M chelonae is 100% citrate positive while M abscessus is 80% citrate negative (Bhalla, Sarao et al. 2018). All these features though useful, are now inferior to currently used molecular techniques.

M chelonae is ubiquitous and has been isolated from soil, water aquatic animals (Falkinham 2002) and usually causes infection following incidental environmental inoculation. It has been identified as causing an increasing number of skin and soft tissue infections (Hay 2009, Kumar, Shrivastava et al. 2021). Localized infection is common after trauma and iatrogenic operation. Disseminated cutaneous manifestations are the most common presentation and occur in patients who are immunosuppressed by malignancy, corticosteroid therapy or other immunomodulating drugs in transplantation (Roy and Weisdorf 1997, Henkle and Winthrop 2015). This case serves to highlight the importance of collaborative work between clinicians and laboratory staff in improving patient care, guiding in treatment decisions, controlling infections, advancing research,

International Journal of Clinical and Medical Case Reports

optimizing diagnostics and promoting ongoing professional development in the medical field.

4. Case presentation

A 4-year-old male (now 5) was born at term with a normal delivery and had no perinatal problems. He had intermittent bony pain in his leg for almost a year before he was diagnosed with Acute Myeloid leukaemia (AML). In September 2021 he developed vomiting followed by a 3-day history of fever, backache, and abdominal pain. He had reasonable energy and no bruising/bleeding. He was seen in Southend hospital where he was noted to be febrile with cervical adenopathy and a blood count showed a white cell count of 186 with thrombocytopenia (platelets 75) and a blood film showed myelomonocytic blasts. He was transferred to Great Ormond Street Hospital (GOSH), a specialised unit that treats and cares for children with cancer on 16/09/2021 where a bone marrow was effaced with myelomonocytic blasts which by flow typed as 59% myeloblasts and 41% monoblasts. The CSF wbc was normal ($1.1 \times 10^6/L$).

Laboratory findings

5 out the 7 Blood cultures were positive (average time to positivity 3- 4 days)

Gram stain= Gram positive bacilli/rods

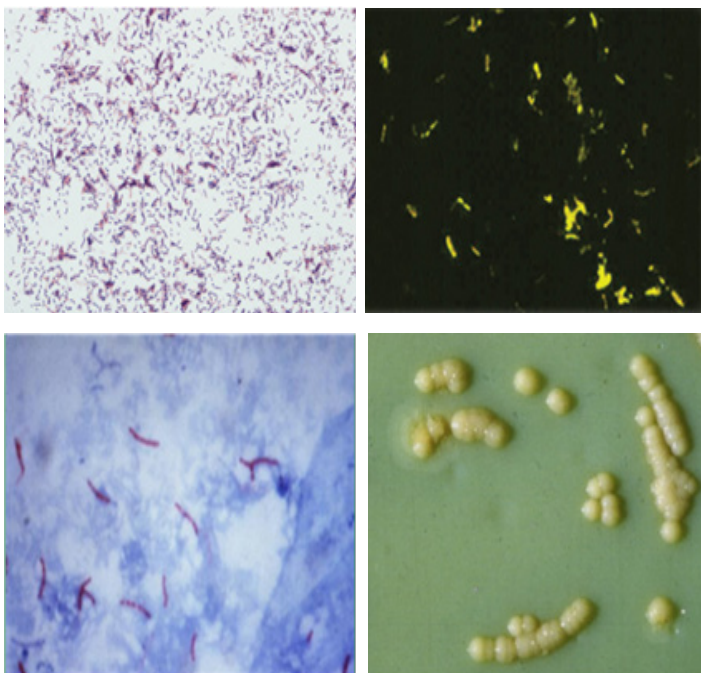
Auramine stain/Zn= AFB Positive

MALD- TOF (in-house) = Failed to provide ID.

Note- No full extraction was attempted.

Reference laboratory ID= M chelonae (WGS)

[CLR=S, AMK=I, CIP=I, DOX=R, FOX=R, LZD=S, MOX=R, SXT=R, TOB=S]



adopted Images (Berman 2019)

Key

- 1) Top left- M chelonae gram stain
- 2) Top right- M chelonae auramine stain
- 3) Bottom left – M chelonae ZN stain
- 4) Bottom right – M chelonae colonies on LJ slope

The patient was diagnosed with high-risk acute myeloid leukaemia (AML), he had received a single dose of Gemtuzumab in induction with MA chemotherapy 24/11/21. It was successful with culture negative febrile neutropenia, which resolved on broad spectrum antibiotics. The patient underwent bone marrow transplant in December 2021. After the bone marrow transplant day 14 (30/12/21) he had fever spike and was treated with multiple antibiotics and antifungal. Day 28 post-transplant was positive for BK virus. He was on prophylaxis dose of antibiotics (PenV, Ciprofloxacin) Antiviral (Aciclovir) and antifungal (Itraconazole). On the 28th of March 2022 the patient was admitted with febrile non-neutropenia/low grade fever, abdominal pain, Boney pain, loss of appetite, weight loss and general weakness. The patient had a BMI of 17.3. On examination, Heart rate (HR) 116, body Temperature of 39 degrees Celsius, respiratory rate of 26, Blood Pressure of 99/58, 100% SpO2 reading and Suspected Sore and infected gastrostomy site, with percutaneous endoscopic gastrostomy (PEG). The patient had a central line, a nasogastric tube, and a PEG. There was no indication for X-ray during and after diagnosis. Between 28/03/22 and the 1/4/2022, a total of seven blood cultures were collected from the patient and sent to a microbiology laboratory in Basildon and Meropenem antibiotic was also prescribed at the same time.

5. Discussion

While gram positive rods in blood cultures are often considered contaminants like diphtheroids, it is essential to exercise caution and perform all the necessary tests to confirm the identity of the microorganism, as they could potentially be mycobacterium species with significant clinical and public health implications. This case report is on a patient with AML who developed line related blood stream infection with Mycobacterium chelonae that was isolated from several blood cultures collected from the patient. When blood cultures are flagged up as positive by the instrument, in this case BD FX, a smear is prepared and stained using gram staining technique. Mycobacterium chelonae will appear as gram positive rods/bacilli (GPRs). These can be in many cases misidentified as diphtheroid or Corynebacterium species and early dismissed as contaminants in a single bottle or one set particularly if blood cultures were collected in accident and emergency department. In this case several sets of blood cultures were collected and five of these were positive with GPRs in gram staining. After gram staining the blood is subcultured onto blood agar and other additional media of the laboratory's choice. For this case a subculture was done onto blood agar, chocolate agar (incubated in CO₂) and an Aria plate that was incubated anaerobically. After 24 hrs incubation there was no growth on the culture plates, at which point the gram was again examined. As the staining result was not typical, a ZN staining was considered and was positive for acid-fast bacilli. After 48 hours plate incubation, there was growth of small white colonies that failed to identify in-house by

International Journal of Clinical and Medical Case Reports

MALDI-TOF instrument without full extraction method. The recovered culture was sent to Mycobacterium reference laboratory that returned the identification as *Mycobacterium chelonae* by whole genome sequencing. A further report soon followed with antibiotic susceptibility results.

Though mycobacterium infection was not suspected at the beginning in this patient, as in other cases where mycobacterium infection is clinically significant, it is helpful and necessary to send several multiple samples for examination to rule out possibility of contamination. Molecular methods especially whole genome sequencing has revolutionised identification of bacteria including mycobacteria and has led to description of new species (Koh 2017, Khieu, Ananta et al. 2021). However, these techniques are not available in all laboratories due to their high cost and complexity. Though commercial hybridization methods are available in most laboratories, their capacity to identify NTM species are limited to fewer than 40 species of the more than 150 recognized species of NTM. The MALD-TOF can therefore provide laboratories with simple, quick, cheap, and accessible technique for the identification of *Mycobacterium* given its large number of species included in its database (AKYAR, Çavuşoğlu et al. 2018, Rodriguez-Temporal, Alcaide et al. 2022). I am confident Identification could have been obtained by the in house MALDI-TOF if full extraction following the manufacturer's instruction had been attempted. This belief is strongly informed by the work of El Khechine and group (El Khechine, Couderc et al. 2011). His group were able to develop a simple extraction protocol for mycobacteria species. EL Khechine et al 's work contributed immensely to building a comprehensive mycobacterial reference database with significance promise for routine laboratories.

Once a diagnosis and clinical significance have been established, adequate antibiotic treatment is required. Current studies indicate that most *M. chelonae* are sensitive to macrolides and aminoglycosides, but full species identification and drug sensitivity testing is recommended, and treatment guided by those sensitivity testing results. For the patients with lines, catheters or pegs, their removal or change should be considered as part of treatment and patient management in addition to antibiotics. In this case, after careful assessment the central line was thought to be source and was removed, and patient continued to be on broad spectrum antibiotics. The patient responded well to treatment, and all follow up blood cultures were negative. Being extra pulmonary mycobacterium infection meant there was no need for CXR, and 6 Month follow up. However, since the patient was immunocompromised continuous monitoring was necessary. The presence of *Mycobacteria chelonae* in hospital environments and equipment also underscores significance of infection control practices and need for vigilant surveillance to safeguard patients especially those that are immunocompromised.

6. Conclusion

In conclusion, this case highlights the potential for *M. chelonae* to cause disseminated infections in immunocompromised individuals, such as those with leukaemia. Recognising and considering atypical pathogens as a differential diagnosis. It also emphasizes the importance of obtaining

blood cultures in febrile patients and considering mycobacterial infections in the differential diagnosis. Early diagnosis and appropriate antibiotic therapy are crucial for successful management of *M. chelonae* infections. Tailored treatment plans are essential especially in paediatric cases where antibiotic choice maybe limited. Immunocompromised patients remain at an increased risk for future infections and therefore require continuous close monitoring. *M. chelonae* is now gaining recognition as a healthcare associated infection and as such need for rigorous infection control measures in healthcare settings.

6.1. Abbreviation key

NTM-Non-tuberculous mycobacterium
 CLR- clarithromycin
 AMK- Amikacin
 CIP- Ciprofloxacin
 DOX- Doxycycline
 FOX- Cefoxitin
 LZD- Linezolid
 MOX- Moxifloxacin
 TOB – Tobramycin
 SXT- Sulphamethoxazole-Trimethoprim
 S- Sensitive
 R – Resistant
 I – Intermediate
 MIC – minimum inhibitory concentration
 WGS- Whole genome sequencing
 GOS- Great Ormond Street
 CXR – chest x-ray

6.2. Ethical approval and Consent to participate.

This is part of the ongoing research on *Mycobacterium* other than tuberculosis (MOTT) in Southend and Basildon NHS foundation Hospitals Catchment with HRA approval (ID30193)

6.3. Consent for publication

Written informed consent was obtained from the patient's legal guardian for publication of this case report and any accompanying images. A copy of the written consent is available for review by the Editor-in-Chief of this journal.

7. Acknowledgement

Many thanks to Emma Parker, the operations manager, IPP Microbiology department Basildon for supporting this exercise and other activities for continuous professional development of staff. Also I appreciate the encouragement of my work colleagues Michael Hembrom, Joy Oloya , Aziter Unger, Hanna Quinn just to name a few

8. Declarations

Availability of supporting data

The data that supports this finding are available at the study site, Mid and South Essex NHS foundation trust.

References

1. Akram S. M, et al. "Mycobacterium chelonae." (2017).
2. AKYAR I et al. "Evaluation of the performance of MALDI-TOF MS and DNA sequence analysis in the identification of mycobacteria species." Turkish Journal of Medical Sciences (2018). 48(6): 1351-1357.
3. Berman J J. Chapter 3 - Bacteria. Taxonomic Guide to Infectious Diseases (Second Edition). J. J. Berman, Academic Press: (2019). 39-119.
4. Bhalla G S, et al. "Methods of phenotypic identification of nontuberculous mycobacteria." Practical Laboratory Medicine (2018). 12: e00107.
5. Brown-Elliott B A. and J V. Philley "Rapidly growing mycobacteria." Tuberculosis and nontuberculous mycobacterial infections: (2017). 703-723.
6. El Khechine, A, et al. "Matrix-assisted laser desorption/ionization time-of-flight mass spectrometry identification of mycobacteria in routine clinical practice." PLoS One 6(9): e24720. (2011).
7. Falkinham J O. "Nontuberculous mycobacteria in the environment." Clinics in chest medicine 23(3): 529-551. (2002).
8. Hay R J. "Mycobacterium chelonae—a growing problem in soft tissue infection." Current Opinion in Infectious Diseases 22(2): 99-101. (2009).
9. Henkle E. and K L. Winthrop "Nontuberculous mycobacteria infections in immunosuppressed hosts." Clinics in chest medicine 36(1): 91-99. (2015).
10. Khieu V, et al. "Whole-genome sequencing analysis to identify infection with multiple species of nontuberculous mycobacteria." Pathogens 10(7): 879. (2021).
11. Koh W.-J. "Nontuberculous mycobacteria—overview." Microbiology spectrum 5(1): 5.1. 11. (2017).
12. Kumar C , et al. "Skin and soft-tissue infections due to rapidly growing mycobacteria: An overview." International Journal of Mycobacteriology 10(3): 293. (2021).
13. Kusunoki S. and T. Ezaki "Proposal of Mycobacterium peregrinum sp. nov., nom. rev., and elevation of Mycobacterium chelonae subsp. abscessus (Kubica et al.) to species status: Mycobacterium abscessus comb. nov." International Journal of Systematic and Evolutionary Microbiology 42(2): 240-245. (1992).
14. Männikkö N. "Etymologia: Mycobacterium chelonae." Emerging infectious diseases 17(9): 1712-1712. (2011).
15. Rodriguez-Temporal D , et al. "Multicentre study on the reproducibility of MALDI-TOF MS for nontuberculous mycobacteria identification." Scientific reports 12(1): 1237. (2022).
16. Roy V. and D. Weisdorf "Mycobacterial infections following bone marrow transplantation: a 20 year retrospective review." Bone marrow transplantation 19(5): 467-470. (1997).
17. Stanford J, et al. "Studies on Mycobacterium chelonae." Journal of Medical Microbiology 5(2): 177-182. (1972).