

Sacral Fracture With Neurological Deficit In A Young Male- A Case Report From Afghanistan

Shafi Ullah Zahid*

Department of Neurosurgery, Jamhuriat Hospital, Kabul, Afghanistan

*Corresponding author:

Shafi Ullah Zahid,

Department of Neurosurgery, Jamhuriat Hospital, Kabul, Afghanistan,

E-mail: shafiullah.zahid.sz@gmail.com

Received: 17 July 2023

Accepted : 11 Aug 2023

Published: 21 Aug 2023

1. Abstract

1.1. Introduction and Importance:

Sacral fractures are relatively rare and complex mostly occur due to high-energy trauma. Isolated sacral fractures occur in 5% of cases, and up to 45% of sacral fractures coexist with pelvic ring injuries. Due to the complex and heterogeneous nature of these fractures, diagnosis and treatment of these fractures remain a challenge for the attending surgeon, and treatment is often determined on a case-by-case basis.

1.2. Case Presentation:

In this article, due to unavailability of the conventional implants, we performed a novel surgical technique where we used two long (110mm) lateral Iliac screws, a rod and a crossbar connecting rod to provide medial-ward pelvic compression.

1.3. Clinical Discussion:

The intervention was tolerated well and led to adequate stability of the fracture. The post op follow-up showed progressive functional and symptomatic recovery, indicating that the technique can be used in case of unavailability of the specialized implants.

1.4. Conclusion:

Simple iliac long screws, orthopedic High-Density Compression Plates (HDCP), rods and a crossbar can be a good alternative for specialized sacral implants in treating Zone III sacral fractures with promising results.

2. Keywords:

Sacrum; Lumbosacral Spine; Sacral Fracture; Neurological Deficit

3. Introduction

The sacrum is a hinge between the vertebral column and the pelvic ring, supporting the upper body weight and playing a fundamental role in

giving stability to the pelvic ring during load-bearing. It is in contact with several critical structures such as nerves, blood vessels, urogenital and other pelvic organs. A fracture of the sacrum is therefore troublesome as it determines an impairment in ambulation and it may represent various associated comorbidities [1]. Sacral fractures are a complex group of fractures occurring in young people following road accidents and falls from height or in the elderly with osteoporosis following trivial trauma. Due to the complex nature, combined with the low incidence of these injuries, surgical management remains a challenge for the attending surgeon [2].

Sacral fractures are classified based on the direction, location, and level of fractures. Three different zones were identified as having characteristic clinical presentations: Zone I, the region of the ala, was occasionally associated with partial damage to the fifth lumbar root. Zone II, the region of the sacral foramina, is frequently associated with sciatica but rarely with bladder dysfunction. Zone III, the region of the central sacral canal, is frequently associated with saddle anesthesia and loss of sphincter function [3]. (figure 1).

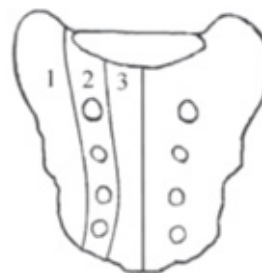

Figure 1: symptomatic and functional recovery.

Sequelae of inappropriately treated or untreated sacral fractures include persistent pain, decreased mobility, neurologic symptoms and deficits to the lower extremities, and urinary, rectal, and sexual dysfunctions [4]. A thorough physical examination, including a detailed neurologic assessment and radiographic evaluation, is necessary to determine treatment. A 2 to 3 mm thin-cut computed tomography (CT) scan with coronal and sagittal reconstruction provides the optimal imaging to identify and evaluate sacral fractures. Magnetic resonance imaging, while not commonly required, can be used to evaluate associated neural compromise in selected cases [5,6]. Stable nondisplaced fractures are usually treated nonoperatively, while significantly displaced fractures require reduction and internal fixation.

Case Presentation

A 45-year-old male was brought to the emergency department complaining of a sharp, deep pain in his rear pelvic area associated with urinary and fecal incontinence, as well as left shoulder pain and deformity. He

International Journal of Clinical and Medical Case Reports

was an unrestrained front-seat passenger when his car collided with an approaching truck on a highway four hours before arriving at the hospital. Since the airbags didn't deploy, the patient's forehead and left shoulder hit the windshield and both of his knees hit the dashboard. He was forcefully extracted from the wreckage by untrained bystanders. He had a brief history of unconsciousness followed by an episode of vomiting. He noticed an immediate development of numbness in his perineum along with urinary and fecal incontinence following extraction from the car. Meanwhile, the rear pelvic pain began and continued to increase in intensity thereafter. His forehead had superficial abrasions that had stopped bleeding, and his left shoulder joint showed profuse swelling, ecchymosis, and visible deformity. His clothes were soaked in urine and fecal matter.

Upon arrival by a road ambulance, a rigid cervical collar was immediately applied and his back was stabilized by an improvised spine board. His neurological status and vitals were examined in the ambulance. The vital signs and mental status were within normal range and stable. GCS was evaluated as 15/15, and sensory examination revealed anesthesia in all perineal dermatomes (S2 to Cx1) with sphincter disturbance, urinary leakage, and hypoesthesia in Rt L5 and S1 dermatomes. He was unable to move his left arm due to severe pain, his Rt lower limb also had constant radiating pain and there was a severe sharp pain in his sacral area, which would increase with the movement of lower limbs. He had no neck pain. The patient's past medical history included chronic low back pain radiating to right leg, which has been conservatively treated for the last 3 years with moderate relief. Otherwise, he was in his normal state of health before the accident.

The patient was directly transferred to the imaging suite under spine precautions. His CT Brain was normal. MRI lumbosacral spine showed a fractured Sacrum at the S1-2 junction with severe canal compromise, and two herniated disks at L3-4 and L4-5 levels severely compromising Rt lateral recesses at both levels (Fig. 2). A CT scan with 3D, sagittal and coronal reconstructions of his pelvis was also performed which revealed sacral fracture of Denis type III, subtype III. Another fracture and angulation at Rt L5 Transverse process was noted as well (Fig. 3).

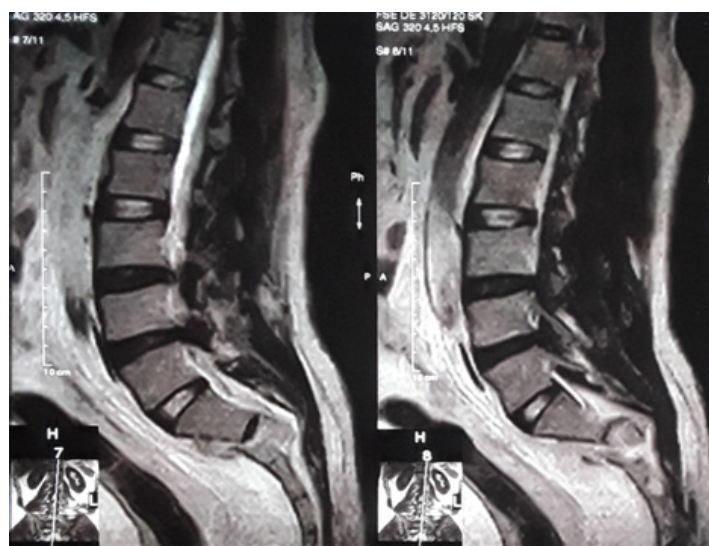


Figure 2: MRI lumbosacral spine showed fractured Sacrum at S1-2 junction with severe canal compromise, and two herniated disks at L3-4 and L4-5 levels severely compromising Rt. lateral recesses at both levels.

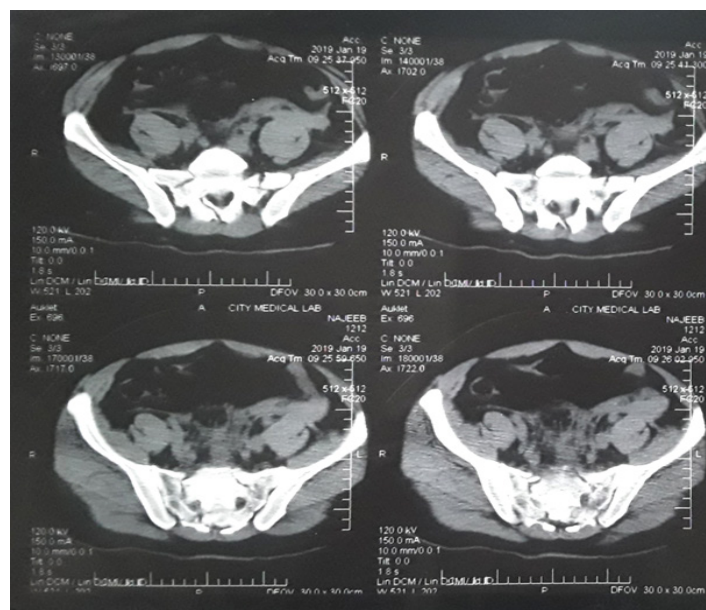


Figure 3: Pre-op CT-pelvis showing left sacral alar, U-shaped and right L5 transverse process fractures

His Lt shoulder joint's radiography revealed a humeral greater tuberosity's avulsive fracture (Fig. 4). The imaging studies were completed within one hour of arrival and decision of surgery was made but due to unavailability of the long sacral screws which has the structure to connect to rods, the surgery could only be started after 10 hours delay with a modified plan.

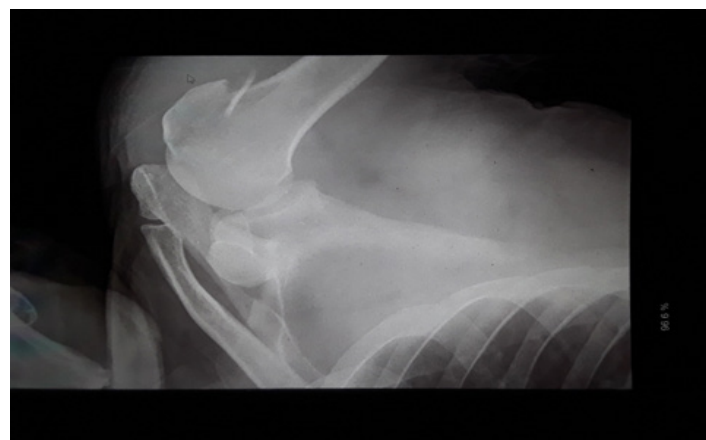


Figure 4: Lt. shoulder joint's radiography revealed a humeral greater tuberosity's avulsive fracture.

Surgery was originally planned to include the following steps:

1. Decompression of the compromised sacral canal
2. Rt L3-4 and L4-5 fenestration and discectomies
3. Transpedicular screw insertion at L4, L5, and S1 levels
4. Long (110mm) lateral Iliac screw insertion with entry at the level of

International Journal of Clinical and Medical Case Reports

S2 plane and rod fixation

5. Crossbar connecting rod application to provide medial-ward pelvic compression.
6. Screw fixation of the avulsed left humeral greater tuberosity.

Sacral canal decompression was performed at the beginning of the procedure followed by Rt. L3-4 and L4-5 fenestration and discectomies (Fig. 5). Since we couldn't find the long screws with Tulips which are directly connectable to rods, we have employed simple 110mm screws which were inserted through the properly adapted and bent orthopedic High-Density Compression Plates (HDCP). The plate fenestrae were checked to also accommodate the transpedicular screws. The plates were bent and adapted to the local anatomy and were placed to cover three levels from the Iliac long screw insertion site to L5 and S1 levels. The L5 and S1 level transpedicular screws were passed through the plate (Fig. 6). The fractured Rt. L5 transverse process could only be partially reduced which was later partially resected to release the exiting nerve root.

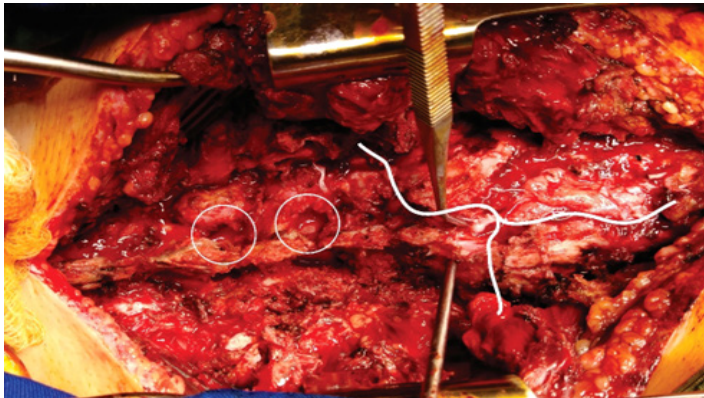


Figure 5: Sacral fracture line (white branched line) and Rt. L3-4 and L4-5 fenestration (white circles)

The final hardware construct included eight screws and two vertical elements: a rod and a plate. Rod and plate overlapped over two levels of L5 and S1; where the screws had a rod at the upper end and the plate at the insertion point (Fig. 7).

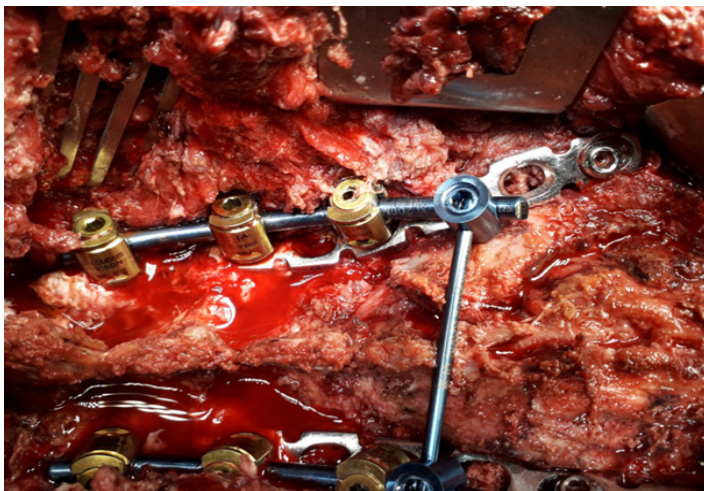


Figure 6: Final structure of the construct where plates are bent and adapted to the local anatomy and are placed to cover three levels from the Iliac long screw insertion sit

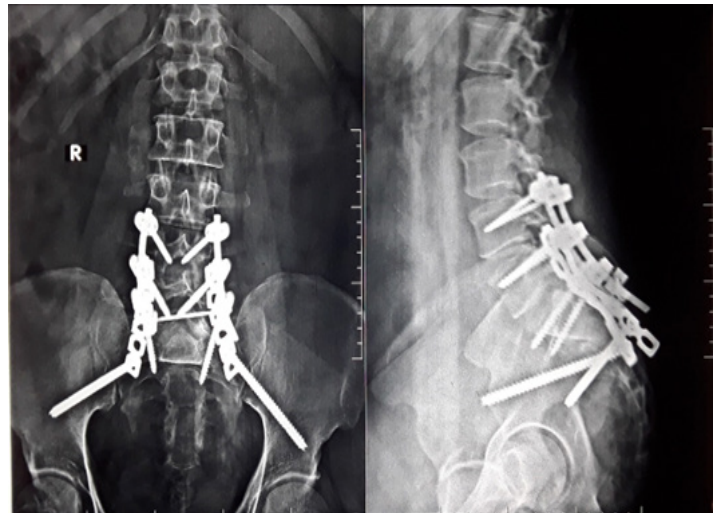


Figure 7: Postoperative X-ray shows the final shape of construct included eight screws and two vertical elements: a rod and a plate. Rod and plate overlapped over two levels of L5 and S1; where the screws had a rod in the upper end and the plate at insertion point

The left humeral greater tuberosity avulsive fracture was fixed with 2 non-cannulated screws (Fig. 8).

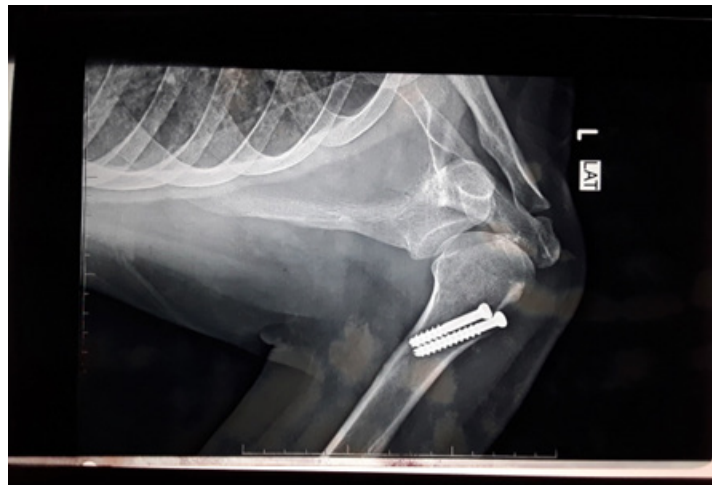

Figure 8: Screw fixation of avulsed greater tubercle.

The patient had an overall excellent recovery. He has since then returned to his job as a civil site engineer.

Two minor issues were encountered during the recovery period: A moderate Rt L5 radicular pain probably originated from the fractured L5 transverse process. It was managed with a local anesthetic and steroid infiltration (Fig. 9a) (Fig. 9b).

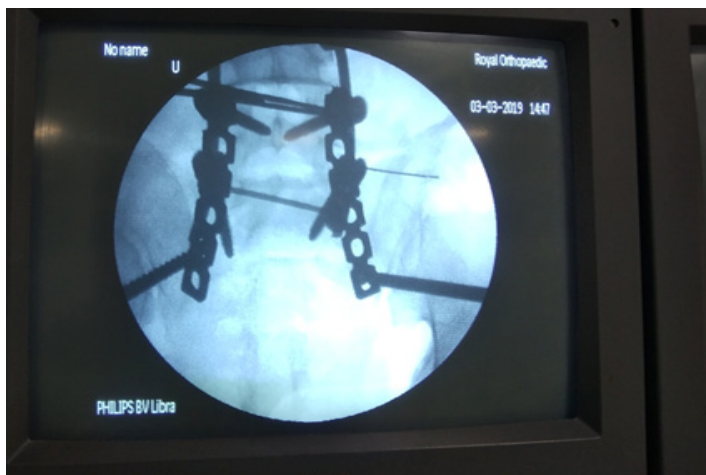


Figure 9a: Rt. L5 extraforaminal infiltration being performed.

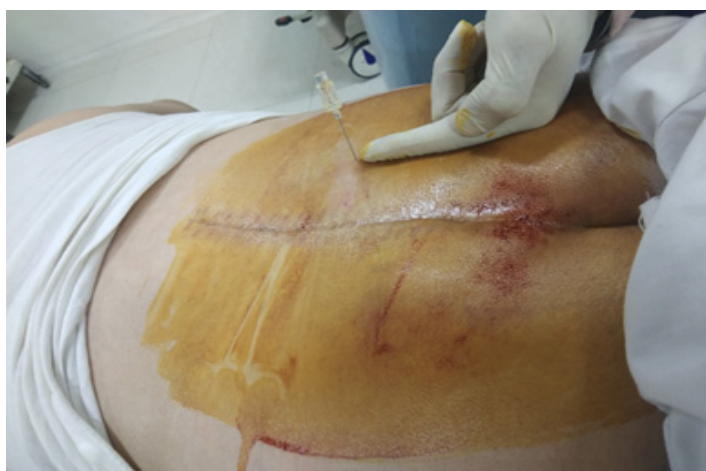

Figure 9b: Rt. L5 extraforaminal infiltration being performed

Lt. buttock tenderness most likely originated from the long screw partially breaching the outer cortex of the Iliac concavity, which resolved over time. He was mobilized on the 18th post-op day with complete symptomatic and functional recovery.

4. Discussion

Sacral fractures are a complex group of fracture that mostly occurs due to high-energy trauma and most commonly occurs due to motor vehicle accidents and falls from an elevation [1]. The diagnosis and management of sacral fractures are challenging and frequently underdiagnosed and mistreated because they commonly present in patients who are neurologically intact. As Denis et al mentioned, close to 75% of patients who present to the hospital with sacral fractures are neurologically intact; thus, the diagnosis is often missed on the initial visit, and patients do not receive optimal treatment [1]. Due to inadequate treatment these patients may develop persistent pain, decreased mobility, and neurologic symptoms and deficits. Since finding specialized long screws for sacral fractures has always been an issue in Afghanistan and similar countries, a novel technique with improvisation of other implants was needed.

5. Conclusion

We reported a 45 years old male with a sacral fracture due to a motor vehicle accident with a neurological deficit (numbness in the perineum with urinary and fecal incontinence). Surgery was done after 10 hours with the modified plan and improvised implants using simple 110mm long screws and orthopedic High-Density Compression Plates (HDCP). The patient responded well to the intervention and was mobilized on post-op day 18 with complete symptomatic and functional recovery.

6. Conflicts of Interest:

All authors certify that they have no affiliations with or involvement in any organization or entity with any financial interest or non-financial interest in the subject matter or materials discussed in this manuscript.

References

1. Santolini E, Kanakaris N K, & Giannoudis P V. Sacral fractures: issues, challenges, solutions. *EFORT open reviews*, 2020; 5(5): 299-311.
2. Rodrigues-Pinto, R Kurd, M F, Schroeder, G. D, Kepler, C K, Krieg J. C, Holstein J H, Bellabarba C, Firoozabadi R, Oner F C, Kandziora F, Dvorak M F, Kleweno C P, Vialle L R, Rajasekaran S, Schnake K J, & Vaccaro A R. Sacral Fractures and Associated Injuries. *Global spine journal*, 2017; 7 (7): 609-616.
3. Hak D J, Baran S, & Stahel P. Sacral fractures: current strategies in diagnosis and management. *Orthopedics*, 2009 : 32(10).
4. Zelle B A, Gruen G S, Hunt T, & Speth S R. Sacral fractures with neurological injury: is early decompression beneficial. *International orthopaedics*, 2004 : 28(4); 244-251.
5. Bydon M, Fredrickson V, De la Garza-Ramos R Li, Y Lehman R A, Trost G R, Gokaslan Z. L. Sacral fractures. *Neurosurgical Focus*, 2014: 37(1).
6. Sabiston C P, & Wing P C. Sacral fractures: classification and neurologic implications. *The Journal of trauma*, 1986 : 26(12): 1113-1115.